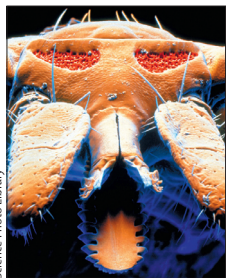




A case of meningoencephalitis by the relapsing fever spirochaete *Borrelia miyamotoi* in Europe

Joppe W R Hovius, Bob de Wever, Maaike Sohne, Matthijs C Brouwer, Jeroen Coumou, Alex Wagemakers, Anneke Oei, Henrike Knol, Sukanya Narasimhan, Caspar J Hodiamont, Setareh Jahfari, Steven T Pals, Hugo M Horlings, Erol Fikrig, Hein Sprong, Marinus H J van Oers



Ixodes ricinus

Lancet 2013; 382: 658

Department of Internal Medicine, Division of Infectious Diseases (J W R Hovius MD), Department of Medical Microbiology (B de Wever MSc, A Oei, H Knol, C J Hodiamont MD), Department of Hematology (M Sohne MD, Prof M H J van Oers MD), Department of Neurology (M C Brouwer MD), Centre for Experimental and Molecular Medicine (J Coumou MSc, A Wagemakers MD), and Department of Pathology (Prof S T Pals MD, H M Horlings MD), Academic Medical Centre, Amsterdam, The Netherlands; Department of Internal Medicine, Division of Infectious Disease, Yale University, School of Medicine, New Haven, CN, USA (S Narasimhan PhD, Prof E Fikrig MD); and National Institute for Public Health and Environment, Bilthoven, The Netherlands (S Jahfari MSc, H Sprong PhD)

Correspondence to:

Joppe W R Hovius MD, Department of Internal Medicine, Division of Infectious Diseases and Centre for Experimental and Molecular Medicine, Academic Medical Centre, Meibergdreef 9, 1105 AZ, Amsterdam, The Netherlands
lyme@amc.uva.nl

See Online for appendix

On April 1 2012, a 70-year-old patient came to our clinic reporting slow cognitive processing, memory deficits, and a disturbed gait, all of which had gradually developed over several months and progressed during the last few weeks before the patient's initial visit. He did not report fever, and he had not been outside the country for several years. He had recently been treated with CHOP (cyclophosphamide, doxorubicin, vincristine, and prednisolone), polychemotherapy, and rituximab (last dose on Aug 2, 2011) for a stage 4 diffuse large B cell lymphoma. His medical history also included *Pneumocystis jirovecii* pneumonia, unexplained chronic diarrhoea, a splenectomy, extensive tick exposure, and two tick bites in the summer and fall before onset of symptoms. On neurological examination there was a distinct bradyphrenia, and on cognitive assessment, the patient scored 26 of 30 points on the mini mental state examination. Vital signs were normal and body temperature was 36.4°C. Cranial MRI showed no abnormalities, but two lumbar punctures showed cerebrospinal fluid pleocytosis with raised protein values. The cause of this chronic meningitis was not identified by wide-ranging microbiological, pathological, and haematological diagnostic testing (appendix). A C6-immunofluorescence assay for *Borrelia burgdorferi* in serum, but not in cerebrospinal fluid, was weakly positive (index 1.8). However, a *B burgdorferi* IgG and IgM immunoblot were non-conclusive and negative, respectively. A *B burgdorferi* sl qPCR in cerebrospinal fluid was negative. Nonetheless, because of the absence of an alternative diagnosis and the progression of symptoms, on April 17, 2012, the patient was treated for a possible Lyme neuroborreliosis with once daily 2000 mg ceftriaxone intravenously for 2 weeks. During several weeks the patient fully recovered. At his last visit to the outpatient clinic in May, 2013, the patient did not have residual symptoms.

Supported by the recent evidence of the presence of *B miyamotoi* in *Ixodes ricinus* ticks across Europe,^{1,2} the relation in time of the patient's symptoms with the tick bites, and his immunocompromised status, we retrospectively considered *B miyamotoi* as the causative agent. We identified motile spirochaetes in stored pre-treatment cerebrospinal fluid by dark-field microscopy (appendix). Additionally, a 16S rDNA pan-relapsing fever *Borrelia* quantitative (q)PCR and a qPCR targeting the *B miyamotoi* flagellin gene was positive in two separate pre-treatment cerebrospinal fluid samples and one pre-treatment blood sample (appendix). Notably, 2.2% of 352 *I ricinus* nymphal ticks from the vicinity of the patient's recreational house in the dunes of Zandvoort, the

Netherlands, proved to be positive for *B miyamotoi* by qPCR (appendix). Amplification and sequencing of the *glpQ* and *p66* genes confirmed *B miyamotoi* as the causative agent and showed 100% identical sequences in ticks and the patient's clinical samples (appendix). We were unable to culture the spirochaetes in modified Barbour-Stoenner-Kelly medium from stored blood and cerebrospinal fluid samples. Finally, ELISA and Western blot did not show anti-GlpQ antibodies in blood and CSF.

Relapsing fever is caused by various *Borrelia* species, which are predominantly transmitted by soft ticks. However, relapsing fever *Borrelia* species have also been identified in hard ticks, including *B miyamotoi* in *Ixodes* ticks.³ *B miyamotoi* infection has been associated with systemic complaints, including malaise and fever, in case series.^{4,5} Recently, in the USA, *B miyamotoi* was shown to be able to cause meningoencephalitis in an immunocompromised patient.⁶ Physicians worldwide managing immunocompromised patients from *Ixodes* tick-endemic areas with a meningoencephalitis should consider *B miyamotoi* as a potential causative agent and should be aware that regular diagnostic tests for *B burgdorferi* will most probably overlook this diagnosis. Whether *B miyamotoi* is also able to cause neurological symptoms in non-immunocompromised patients requires further investigation.

Acknowledgements

JWRH, MS, MCB, CJH, STP, and MHJvO took care of the patient. JWRH, BdW, JC, AW, AO, HK, SN, SJ, HMH, EF, and HS contributed to retrospectively establishing the diagnosis. JWRH, BdW, SJ and HS interpreted the PCR and sequencing data. JWRH drafted the manuscript and all authors contributed to writing the manuscript. Written consent to publish was obtained. Finally, we are grateful to Manoj Fonville and Paul Hengeveld for their outstanding technical support.

References

- Geller J, Nazarova L, Katargina O, Jarvekul L, Fomenko N, Golovljova I. Detection and genetic characterization of relapsing fever spirochete *Borrelia miyamotoi* in Estonian ticks. *PLoS One* 2012; 7: e51914.
- Subramanian G, Sekeyova Z, Raoult D, Mediannikov O. Multiple tick-associated bacteria in *Ixodes ricinus* from Slovakia. *Ticks Tick Borne Dis* 2012; 3: 406–10.
- Fukunaga M, Takahashi Y, Tsuruta Y, et al. Genetic and phenotypic analysis of *Borrelia miyamotoi* sp. nov., isolated from the ixodid tick *Ixodes persulcatus*, the vector for Lyme disease in Japan. *Int J Syst Bacteriol* 1995; 45: 804–10.
- Krause PJ, Narasimhan S, Wormser GP, et al. Human *Borrelia miyamotoi* infection in the United States. *N Engl J Med* 2013; 368: 291–93.
- Platonov AE, Karan LS, Kolyasnikova NM, et al. Humans infected with relapsing fever spirochete *Borrelia miyamotoi*, Russia. *Emerg Infect Dis* 2011; 17: 1816–23.
- Gugliotta JL, Goethert HK, Berardi VP, Telford SR III. Meningoencephalitis from *Borrelia miyamotoi* in an immunocompromised patient. *N Engl J Med* 2013; 368: 240–45.